

# Therapeutic aesthetics

Linda Greenwall examines the wider oral health benefits of bleaching compounds and trays

With the success of tooth whitening treatments, several health benefits have emerged that can improve patients' oral health (Li and Greenwall 2013).

Utilising these resulting health benefits and developing them further can help the clinician create a programme that improves patients' dental health throughout the different periods of their lives. The purpose of this article is to discuss this further and elaborate on the benefits of introducing a programme of therapeutic aesthetics as part of an oral health maintenance programme and helping the patient to achieve sustainable health.

## What is therapeutic aesthetics?

Therapeutic aesthetics is the process of sustaining a patient's oral health while improving and maintaining the aesthetic health of their teeth. The bleaching tray can be transformed into a therapeutic tray to deliver chemicals that help the patient achieve a sustained health gain throughout their lives.

The trays are used for different purposes throughout a patient's life. This may be related to a high caries susceptibility at a young age or an elderly patient who is experiencing dry mouth from multiple medications.

The trays are worn to undertake a therapeutic use, whether that is to reduce caries, reduce the high risk classification of a caries exposure, reduce root caries, or assist with protecting the mouth during and post-radiation treatment.

## Tooth whitening materials

The two main materials used in tooth whitening are both derived from hydrogen peroxide. Hydrogen peroxide is used as a day product. When hydrogen peroxide is placed into a tray, it mixes with saliva and releases water and oxygen as effervescent bubbles.



## Education aims and objectives

This clinical article aims to present some of the wider oral health benefits that leveraging bleaching trays for therapeutic treatments can bring.

## Expected outcomes

Correctly answering the questions on page xx, worth one hour of verifiable CPD, will demonstrate that the reader has read and understood the principles of therapeutic aesthetics and how they can be used to help patients maintain good oral health for a lifetime.

The oxygen penetrates into the enamel and dentine, and reaches the pulp within five to 15 minutes. Hydrogen peroxide flows multi-directionally, expanding in three dimensions and also tracking into the gingival crevice and pockets.

The liberation of oxygen into the gingival crevice changes the bacterial environment to remove the gram-negative bacteria, cleanse the pocket and stimulate healing to take place. All the oxygen is released within one hour, so there are no further benefits of using the material for longer than an hour.

Carbamide peroxide, however, is a slower-release material. It contains carbopol, which allows oxygen to be released slowly over a period of eight to 10 hours.

Carbamide peroxide breaks down into urea and ammonia. Urea elevates the pH in the mouth, stimulating healing. It is also thought to reduce caries by elevating the pH of the mouth to a level above that at which the caries process can comfortably occur, in addition to debriding the teeth and improving gingival health. It heals the soft tissues and gingival areas.

Ammonia and carbon dioxide are also released from carbamide peroxide, though these are considered to be by-products.

Most of the at-home bleaching materials also contain fluoride or potassium nitrate to act as soothers. These help to reduce the likelihood of sensitivity and reduce areas susceptible to caries. Within five minutes of the application of the material in the tray, salivary pH is elevated for a period of two hours. The pH in the tray also remains raised for two hours (Haywood 2007).

## Benefits of tooth whitening

There are a number of benefits associated with tooth whitening:

## What is therapeutic aesthetics?

Transforming the bleaching tray to a therapeutic tray to deliver chemicals to help the patient achieve a health gain. Materials to place in the tray include:

- Carbamide peroxide
- Fluoride
- Potassium nitrate
- Amorphous calcium phosphate
- Other medications according to the patient's needs

## Teeth

Whitens and lightens the teeth, reduces stain build-up on teeth, preserving tooth structure.

## Gingivae

- Reduces gingival inflammation
- Reduces gingival swelling
- Reduces plaque formation
- Reduces extrinsic stain build up
- Reduces plaque adherence onto teeth
- Reduces gingival bleeding
- Improvement in gingival index scores.

## Soft tissues

- Improvement in soft tissue, healing of soft tissue lacerations
- Improvement in wound healing in the mouth.

## Oral health

- Improvement in oral hygiene as the patient looks in the mirror to see the whiter teeth
- Teeth whitening, brightening and lightening
- Reduction in caries formation (Lee et al 2005)
- Reduction in root caries formation
- Teeth feel cleaner as a result of the improved oral hygiene.

## Patient effects

- Improves patients' self esteem and self-worth
- Patients smile more

## Other benefits

- Tooth whitening materials have antibacterial properties which help to heal the mouth (Lazarchik and Haywood 2010).
- A reduction in oral malodour (DeVizio 2008)
- Carbamide peroxide was originally used as an oral antiseptic
- Patients are walking adverts for the practice.

## History

Over the last century, hydrogen peroxide has been used as a treatment for reducing gingival inflammation. Initially patients were instructed to use hydrogen peroxide mouthwash on a toothbrush to help reduce gingival swelling and irritation. In 1968, the orthodontist Bill Klausmier advised his patients to use 3% hydrogen peroxide mouthwash in their retainers after completing orthodontic treatment. At the six-month evaluation he noted that not only was the gingival inflammation reduced, but the teeth were significantly whiter. He developed and used this technique over the next 40 years and wrote a retrospective report about it. Klausmier wrote that in the 40 years of using the orthodontic retainer to apply the mouthwash to reduce the inflammation and also to whiten the teeth, nobody lost a tooth, needed a root canal or damaged a tooth as a result of the technique. Since then, whitening gels have changed significantly and have become much thicker and more viscous, thus adhering to the trays more in order to deliver the materials more effectively.

## Delivering materials

Using the tray as a delivery vehicle, various chemicals can be placed in order to deliver sustained health benefits to the teeth over a chosen period of time according to the effectiveness of the material as it is released. The placement of the tray helps to keep the material in situ even if it comes into contact with saliva. The tray can be made of flexible material such as Evacryl or a rigid material such as that used for orthodontic Essix retainers. The various materials are applied into the trays. The concept is that the tray remains in place overnight while the materials are soaking into the teeth or gingivae.

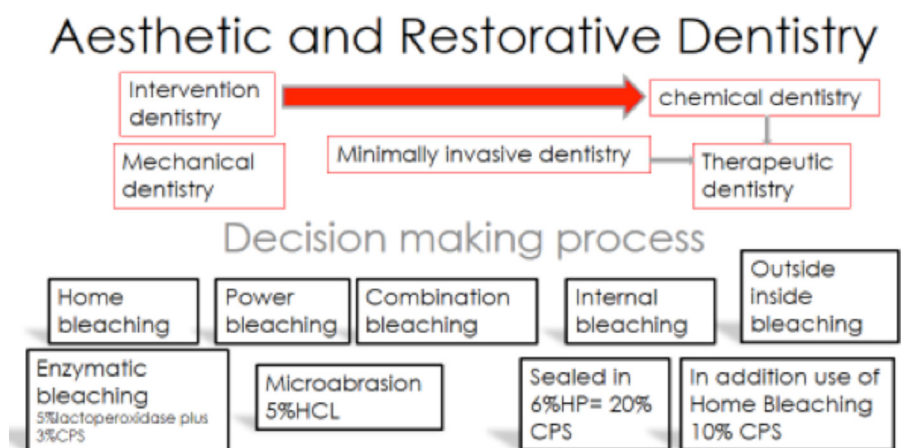
## Tray design for therapeutic use

When it comes to therapeutic uses, tray design can be varied (and multipurpose), depending on the material being used. That said, a scalloped

Aetiological classification	Appearance classification
Hereditary	Size (small/medium/large)
Trauma	Depth (deep/shallow/flecks)
Fluorosis	Appearance (bright/faint/opaque white spot)
Decay hypomineralisation	
Molar incisor hypoplasia (MIH)	
Congenital premature birth	

**Table 1: White spot lesions**

The first line of defence when treating white spot lesions due to decalcification is improvement in oral hygiene, reduction of sugary food and the use of the therapeutic tray with fluoride gel inside to reduce the appearance of the white spots that are due to demineralisation. Some spots are easier to treat than others.



**Figure 1.** Concept of therapeutic aesthetics in aesthetic and restorative dentistry

tray is often a useful design, as this avoids impinging on the gingivae. The tray margins are cut just next to the gingival crevices. An orthodontic aligner can be used as a therapeutic tray as well as a retainer.

## Suitable tray types

There are a variety of tray designs that can be used and modified for therapeutic use:

1. Aligners
2. Retainers such as an Essix retainer
3. Bleaching trays
4. Specially designed trays similar to a bleaching trays, using a thicker strength material for extended wear time

Using the therapeutic trays throughout the patient's life depends on health need.

There are times in a patient's life when they may be subjected to additional health challenges. This puts them at risk for tooth decay, root decay, gingival inflammation and dry mouth.

## Who can benefit?

1. Those with special needs
2. Those high risk of tooth decay

3. Dry mouth suffers
4. Elderly patients (Kelleher et al 2011)
5. Chemotherapy patients
6. Patients have radiation therapy
7. Patients suffering from gingival and periodontal conditions
8. Patients suffering from white spots for aesthetics
9. Patients who are immuno-compromised
10. Patients with eating disorders or acid reflux.

## Elderly patients

Many elderly patients take multiple medications, which can reduce saliva flow and cause them to suffer from xerostomia (dry mouth). Some patients suck mints to relieve this, which exacerbates the condition.

The lack of saliva can make patients more susceptible to root decay and increase decay around the margins or crowns. A study by Van Haywood (2007) has shown that using a nightly bleaching tray with carbamide peroxide can reduce that susceptibility to root caries.

The whitening material kills caries bacteria and reduces plaque adherence on the teeth.



**Figure 2:** Carbamide peroxide bleaching gel is placed into the middle of the tray

Furthermore, elderly patients who have difficulty holding a toothbrush may find it easier to apply the carbamide peroxide gel and place this in the mouth overnight.

### Special needs patients

In a study undertaken by Lazarchik and Haywood 2010, the authors found 10% carbamide peroxide delivered in a custom-fitted tray to be an effective treatment for caries in patients with compromised oral hygiene. Plaque suppression and caries control resulted from a carbamide peroxide-induced increase in salivary and plaque pH caused by its urea component, and from possible antimicrobial action via physical debridement and the direct chemical effect of hydrogen peroxide.

### Patients at high risk of decay

There are many people in this category that can be helped by the use of therapeutic trays.

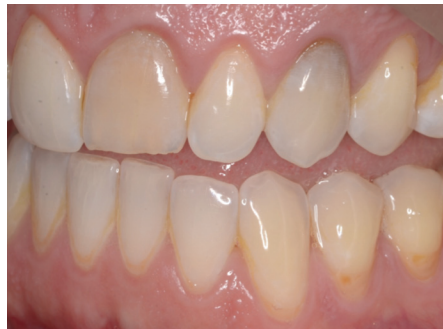There may be patients who have poor oral hygiene and cannot maintain a clean mouth. Patients with a high sugar diet, patients that are immunologically compromised and have a poor diet and cannot maintain their oral hygiene. Some patients who have eating disorders or who have reflux and acid regurgitation problems can also be helped by the use of a therapeutic tray.

These patients can use carbamide peroxide gel to help reduce the plaque and also may place amorphous calcium phosphate into the tray to help elevate the pH further while restoring the oral environment to a neutral pH.

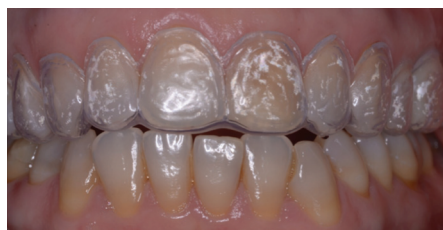A concentration of 10% carbamide peroxide kills lactobacillus, one of the bacteria that causes tooth decay. Chlorhexidine kills streptococcus mutans bacteria, which is also responsible for tooth decay.

### Salivary changes inside the tray

The research from Leonard et al 1994 has shown that when saliva comes in contact with carbamide peroxide there is an elevation in pH,



**Figure 3:** Early root caries in a patient who also wants to whiten his teeth. See the early root decay on the lower left first and second premolars. The patient's brushing techniques were revised and after completing the whitening treatment, the patient continued to use the tray twice a week placing amorphous calcium phosphate inside to reduce the demineralisation on the root surfaces



**Figure 5:** A patient with the upper bleaching tray in place. This treatment involved whitening followed by placement of chlorhexidine gel inside the tray after completing the crown lengthening surgery undertaken for the upper left first molar. The bleaching tray was placed after surgery to help heal the palatal area

which raises to a value of about pH 8 due to the liberation of urea. The urea and ammonia are byproducts of the breakdown process of the carbamide peroxide. Hydrogen peroxide breaks down to water and oxygen.

The critical pH for demineralisation is 5.2-5.5 for enamel and 6.0-6.8 for dentine (Leonard et al 1994b).

### References

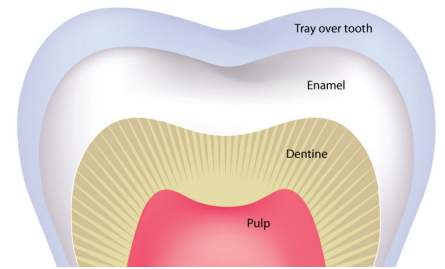
DeVizio W (2008). The efficacy of a new dentifrice with caries, plaque, gingivitis, calculus, tooth whitening, and oral malodor benefits. *J Clin Dent* 19(3): 79-80

Haywood VB (2007) Bleaching and Caries Control in Elderly Patients. *Aesthetic Dentistry Today* October 1:4 42-44

Kelleher MG, Djemal S, Al-Khayatt AS, Ray-Chaudhuri J, Briggs PF, Porter RW (2011). Bleaching and bonding for the older patient. *Dent Update* 38(5): 294-6, 298-300, 302-3

Lazarchik DA, Haywood VB (2010). Use of tray-applied 10 percent carbamide peroxide gels for improving oral health in patients with special-care needs. *J Am Dent Assoc* 141(6): 639-46

Lee SS, Zhang W, Lee DH, Li Y (2005) Tooth whitening in children and adolescents: a literature review. *Pediatr Dent* 27(5): 362-8



**Figure 4:** Cross-section of a tooth demonstrating the therapeutic tray in place over the tooth



**Figure 6:** Close-up cross-section of the therapeutic tray for placement of various materials for different purposes

### Summary

The use of carbamide peroxide in a bleaching tray has additional benefits to help patients improve and maintain their oral health. Dentists are advised to consider this therapeutic approach to improve aesthetics while improving health sustainability for many patients. Many patients can benefit from this approach.

Leonard RH, Austin SM, Haywood VB, Bentley CD (1994). Change in pH of plaque and 10% carbamide peroxide during nightguard vital bleaching. *Quintessence Int* 25: 819-823

Leonard RH, Bentley CD, Haywood VB (1994a). Salivary pH changes during 10% carbamide peroxide bleaching. *Quintessence Int* 25: 547-550

Li Y, Greenwall LH (2013). Safety issues of tooth whitening using peroxide-based materials. *Br Dent J* 215(1): 29-34. doi: 10.1038/sj.bdj.2013.629.

Nathoo S, Mateo LR, Delgado E, Zhang YP, DeVizio W. (2011) Extrinsic stain removal efficacy of a new dentifrice containing 0.3% triclosan, 2.0% PVM/MA copolymer, 0.243% NaF and specially-designed silica for sensitivity relief and whitening benefits as compared to a dentifrice containing 0.3% triclosan, 2% PVM/MA copolymer, 0.243% NaF and to a negative control dentifrice containing 0.243% NaF: a 6-week study. *Am J Dent* 24 Spec No A:28A-31A