

# Treatment options for peg-shaped laterals using direct composite bonding

**Linda Greenwall** BDS MGDS RCS MSc MRD RCS FFGDP discusses the various treatment options for these particular teeth

## Introduction

Smiles are important to young and old. In the appearance related society that we live in, the younger adolescent patient can easily become self conscious if their teeth are different to others. More adolescents than ever are concerned about their appearance because of the society of ready access to media and television shows. A culture of having the perfect body and perfect smile has developed in the last decade. Adolescents and adults want to have a perfect body, a perfect smile and a perfect face. There exists tremendous peer pressure to conform to society norms. Adolescents notice if their teeth are different to others and that do not conform to the ideal of a beautiful smile.

When peg-shaped laterals erupt in the mouth, it can be a disappointment to the patient that their teeth are not perfect or too small in comparison to the rest of the anterior teeth. Peg-shaped lateral teeth occur commonly. There are many new conservative options that are possible using direct and indirect composite resin material. It is essential to discuss these options with patients, their parents and the interdisciplinary team that are involved in treatment. The diagnosis of peg-shaped laterals occurs when these teeth erupt. It is essential that all options are discussed with patients as it involved early decision making. It is the intention of this article to discuss peg-shaped laterals and the conservative treatment options that are available. Different treatments are carried out for peg-shaped laterals depending on the circumstances and the smile design.



**Linda Greenwall** BDS MGDS MRD MSc FFGDP is a specialist in Prosthodontics and Restorative Dentistry and runs a multi disciplinary private practice in Hampstead, London. She is editor in chief of *Aesthetic Dentistry Today* magazine and has written a book called 'Bleaching Techniques in Restorative Dentistry an Illustrated Guide' which was awarded Best New Dental Book of the Year 2001. Linda lectures all over the world on all aspects of combining Bleaching with Aesthetic and Restorative Dentistry. She is also the President of the British Bleaching Society.

## Education aims and objectives

The aim is to educate the reader on the various options available to treat peg-shaped laterals using direct composite bonding through a demonstration of case studies.

### Expected outcomes

The reader will understand the benefits and disadvantages of direct composite bonding for peg-shaped laterals. They should be prepared for careful interdisciplinary treatment planning to obtain aesthetically pleasing results.



## Incidence of peg-shaped laterals

A peg lateral is defined as 'an undersized, tapered, maxillary lateral incisor' (Glossary of prosthodontic terms (1990) that may be associated with other dental anomalies, such as canine transposition and over retained deciduous teeth. Individuals with malformed lateral incisors often display a diastema in the midline region caused by the distal movement of the central incisor. There are many acquired and inherited developmental abnormalities that alter the size, shape and number of teeth peg-shaped laterals are also known as cone-shaped lateral incisor, which is a form of microdontia.

This may be inherited as a dominant trait (Meskin 1963). If both parents have 'peg laterals', the homozygous child will have total anodontia of succedaneous teeth (Witkop 1987). The lateral teeth are the most common to be smaller in size. The prevalence of peg-shaped maxillary lateral incisors has been reported to be higher than the prevalence of other developmental malformations of teeth. In a study by Backman and Wahlin (2001), the incidence of peg-shaped incisors was found to be 0.8% in 739 Swedish children. The occurrence of hypodontia together with the development of malformations of permanent teeth was found to be 4% (Al Emran 1990).

Other reports have described the association between the presence of peg-shaped maxillary laterals and other developmental anomalies, with one study (Peck 1993) showing increased occurrence on the upper left side of the mouth.

## Diagnosis and assessment of the smile needs to be undertaken prior to treatment

This will involve a full clinical consultation, discussion with the patient and parents on their concerns and requirements. A full smile analysis will need to be undertaken. This may also involve diagnostic study models and putty stents which are sectioned to help build up the composite to the correct shape. The gingival heights of contours and full gingival and periodontal screening will need to be undertaken.

Normally the initial treatment will involve orthodontic treatment to realign the lateral incisor tooth and then the simple treatment options will be direct composite bonding. As the gingivae of many of the patients is immature, further natural recession of the gingivae will take place as the patients mature. Many of the patients who have recently completed orthodontic treatment have swollen and inflamed gingivae (see Case 1) which can appear hyperplastic. This normally resolves once the braces are removed and with the introduction of good oral hygiene methods. Sometimes the gingivae will require crown lengthening surgery (see Case 5) to create the correct crown heights which should be in harmony with the central incisor teeth (see Case 3).

## Treatment options for peg-shaped laterals

There are various treatment options available. See Table 1. It is essential to discuss all options with patients so that they are involved in the

decision making process. It is also necessary to seek the assistance of the orthodontist and the periodontist in planning treatment for the patient.

## Interdisciplinary planning of treatment for peg-shaped laterals. Treatment in combination with orthodontic treatment

It is essential that prior to any orthodontic treatment, full discussions are held with the restorative dentist, the patient, the patient's parents and the orthodontist. This way all treatment options are fully discussed and outlined. The risks and benefits of all treatment can be discussed and outlined and any future long term restorative needs can be outlined. Restorative and aesthetic treatment for an adolescent patient may need to be undertaken in phases as the patient matures. Some composite bonding treatment can be undertaken immediately after braces are completed prior to making the orthodontic retainers whether these are Essix type full arch clear plastic retainers or direct bonded lingual retainers.

Timing and sequencing of appointments is essential towards the end of orthodontic treatment so that restorative treatment can be well coordinated at the correct appointment sequence. Sequential treatment may include orthodontic treatment first followed by direct bonding. At a later stage porcelain veneers may be placed when the patient is in their twenties. The results of most of the direct bonding is excellent. The new materials lend themselves to create highly aesthetic natural looking teeth. The composite materials can be well finished and polished to give excellent aesthetics and restoration longevity.

## The orthodontic management of peg shaped laterals

There are several treatment options to consider for peg laterals. Counihan (2000) recommends that there are two basic approaches. First, the lateral incisor can be extracted and the resultant space closed. However, this will often give a narrow unaesthetic smile. The canine is too yellow and the gingival margin is too high. The second, preferred, option is often to open the space mesial and distal to the peg-lateral and create a proper space for a normal-sized lateral incisor (see Case 2 Figure 6). The restorative dentist has to build up the peg-lateral to simulate a normal-sized lateral incisor. It is best to discuss the positioning of the peg lateral within this space. Should it be close to the central incisor, in the middle of the space or to the distal of the space. This will depend on the actual size of the peg lateral and the amount of avail-

able space that can be created for the lateral incisor tooth.

## Undertaking treatment using a phased approach

Why use direct bonding? A direct composite bonding is an ideal treatment for peg shaped laterals as it is conservative and can be placed directly onto the tooth. The aim of the treatment is to close the diastema and restore the contours of the tooth (Inzgi 2005). See Tables 2 and 3.

These direct bonded composite restorations can be undertaken quickly in a matter of hours. They offer great flexibility in that the restorations can be added to easily. Shapes can be changed including additions to the length and width of the teeth. Composite can be added to the teeth to give the illusion that changes are made to the angulation and alignment of the teeth.

## Follow up and monitoring

It is essential to review the patient one week following treatment so that the final shade of the composite can be checked. As treatment is carried out on isolated teeth which become dehydrated the choice of the shade of composite can be too light. It is thus essential to review the patient and repolish any rough edges and also check the functional occlusion again. Patients should be instructed in good oral hygiene and should see the hygienist regularly to maintain excellent integrity of the composite tooth margins. Any staining can be polished off by the hygienist using a disc and a rubber wheel. The bonding can be repolished and buffed using the special polishing discs.

## Complications and longevity of treatment. See Table 3.

### Longevity of treatment:

There are numerous studies which have been conducted on the longevity of restorations used to treat peg shaped laterals and to close diastemata. Walls et al (1988) conducted a two-year clinical trial of a composite laminate veneer system for masking discoloration or hypoplasia on the anterior teeth of patients has been undertaken. Three hundred and twenty restorations were placed in 79 patients, of these 273 restorations in 68 patients have been followed over a two-year period. The technique produced an acceptable improvement in the aesthetics of the patients in the trial. However, the composite veneers were susceptible to chipping (52% of lateral incisor veneers and 79% of central incisor and canine veneers showed some evidence of material loss after two years) and marginal staining (75% of

**Table 1:**

Treatment options for peg shaped laterals

1. No treatment, patient not concerned
2. Orthodontic treatment first to align the teeth in the arch
3. Direct composite bonding onto peg laterals
4. Indirect composite placement
5. Bonded crowns
6. Porcelain bonded to metal crowns (Bello 1997)
7. Crown lengthening surgery to get better gingival heights than direct bonding.
8. Extractions and implant placement
9. Combinations of treatment in different sequences

**Table 2:**

Benefits of direct composite bonding

1. Preserve sound tooth structure (Inzgi 2005).
2. Can be placed directly onto the tooth surface
3. Can place as a type of direct composite veneer
4. It is a conservative restoration
5. Can easily change the emergence profile and angle
6. Can alter the shapes and length of the tooth
7. Can close diastemata
8. Can be used as an interim restoration in an adolescent and added to as the gingival heights matures
9. Can be repaired easily
10. Can be polished and repolished to a high shine
11. Long lasting
12. Not expensive treatment option

**Table 3:**

Disadvantages of direct composite bondings

1. Can chip and break
2. Can discolour of older composite used
3. Can develop leakage marginal leakage (Walls 1988)
4. Can pick up stain easily in those patients who smoke and have poor oral hygiene
5. Can have a deleterious effect on gingival health on patient with poor oral hygiene (Walls 1988)

## Case 1

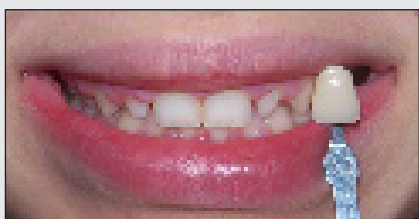


Figure 1: This young patient first had a course of orthodontic treatment to align the rest of the teeth. Orthodontic treatment which was undertaken by Dr Robert Katz, was aimed at aligning the occlusion and creating the correct space for restorative treatment of the peg shaped laterals. This figure shows the appearance on the teeth immediately after completion of orthodontic treatment and the removal of braces. To improve the post orthodontic gingival hyperplasia a course of hygiene therapy was undertaken and the teeth were polished to remove the existing staining. The retainers that were made were used as bleaching trays. The uneven gingival height discrepancy between the centrals and the lateral incisors was assessed. Due to the young age of the patient, 14 years old, decisions were made to continue to monitor this as the patient gets older and to review the gingival maturation. Crown lengthening surgery may be necessary when the patient is older. Indirect composite bondings were made in the laboratory as it would save chair side time for a young patient. The material (Symphony 3M) that was used to make the bondings can be added directly in the mouth as the patient matures and the gingivae change shape. This build in flexibility to preserve the life of the bondings which can be re adapted, re-shaped and repaired as the patient ages

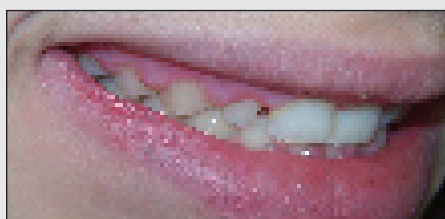


Figure 2: The lateral view of the gingivae and the right lateral incisor showing spacing after removal of the orthodontic brackets. As the two central incisor teeth are large square and dominant, the treatment was planned so that the peg shape lateral tooth was aligned into the middle of the space so that the correct width of the lateral to central incisor could be created from the mesial and distal sides

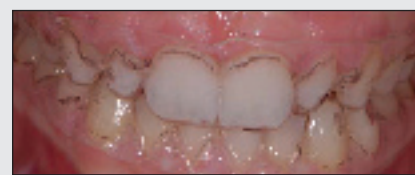

Figure 3: The retainers were used as bleaching trays and the teeth were bleached for 10 days using 10% carbamide peroxide

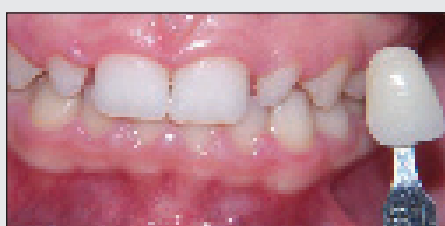

Figure 4: The appearance of the teeth after whitening. Note the immediate improvement in gingivae and the improvement of oral hygiene

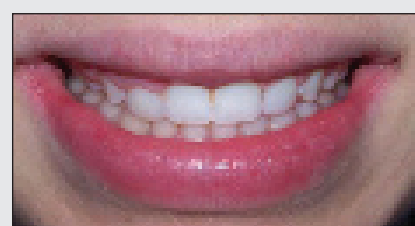


Figure 5: After completion of bleaching treatment a much whiter colour was achieved. The teeth shade went from an A3.5 to a B1 shade. Impressions were made of the existing laterals and indirect composite restorations were made in the lab. These were cemented at chairside a few days later on the lateral incisor teeth

## Case 2:

This patient with peg-shaped laterals had orthodontic treatment undertaken by Dr Gerry Bellman. In this case due to the shape and size of the peg shaped laterals these teeth were aligned more towards the central incisors so that there would be less visible spacing on the mesial side at end of treatment and less bonding would be necessary

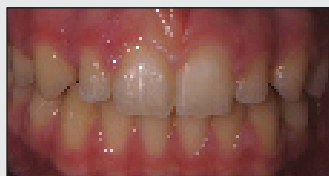

Figure 6: View after removal of the orthodontic brackets. These peg shaped laterals were aligned orthodontically to close proximity to the central incisors

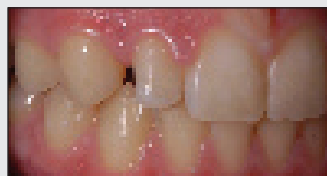


Figure 7: Right Lateral view prior to bonding

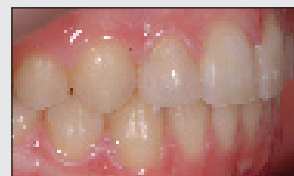

Figure 8: Right lateral view after bonding

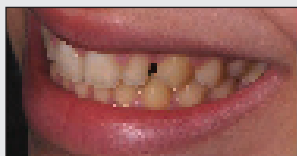


Figure 9: Left lateral view before bonding

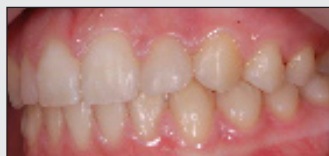

Figure 10: Left lateral view after composite bonding. Composite material was added to the distal, buccal and mesial sides to achieve close of the distal diastema and to build up a harmonious buccal and mesial contour

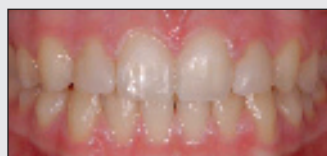

Figure 11: The Final view of the composite bondings to the peg shaped laterals to close diastemas and improve the shapes of these lateral teeth.

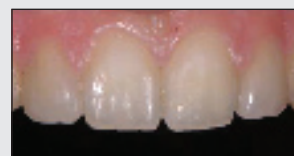

Figure 12: Final view of direct composite bonding to the lateral incisors. Composite material was added to the distal and mesial sides of both lateral incisors. It was added to the distal side to close the diastemata. It was added to the mesial side to improve the labial contour and to improve symmetry and harmony from the centrals to the lateral incisors

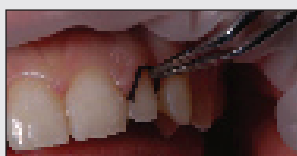


Figure 13: Isolation is essential when placing direct composite bonding to avoid saliva contaminating the enamel surface when bonding. A size small Optragate (Vivadent (UK) was placed over the lips to achieve good isolation. Here a black gingival retraction cord (Optident, Ikley Yorkshire) was placed in order to assist with correct contouring and flow of the composite from the natural tooth to the diastema area. This also minimises the flow of crevicular fluid which could interfere with bonding

veneers showed some evidence of marginal staining after two years) during function. The veneer restorations had a deleterious effect upon the gingival health of the teeth on which they were placed. However this study is now 20 years old and with the newer stronger composite materials there should be a higher success rate with many clinical examples lasting 20 years.

## Summary

The common occurrence of peg-shaped laterals is such that practitioners should be prepared for the careful interdisciplinary treatment planning to obtain excellent results. Through these discussions with specialist colleagues a staged approach can be undertaken with orthodontic treatment the first part of the treatment plan. This is followed by simple direct composite bondings to treat peg lateral teeth prior to the final retention phase of the orthodontic treatment. Appointments should be carefully co-ordinated so that this type of treatment can be efficiently and successfully carried out.

## References

- Al-Emran, S (1990). Prevalence of hypodontia and developmental malformation of permanent teeth in Saudi Arabian school-children, *Br J Orthod* 17 pp. 115–118
- Backman B. and Wahlin Y.B., Variations in number and morphology of permanent teeth in 7-year-old Swedish children, *Int J Paediatr Dent* 11 (2001), pp. 11–17s
- Bello A and Jarvis RA (1997) A review of esthetic alternatives for the restoration of anterior teeth, *J Prosthet Dent* 78 pp. 437–440
- Counihan D. (2000) The orthodontic restorative management of the peg lateral. *Dental Update* June 27 (5) 250-6
- Glossary of prosthodontic terms, *J Prosthet Dent* 81 (1999), p. 90
- Izgi AD, and Emrah A (2005) Direct restorative treatment of peg shaped maxillary lateral incisors with resin composite: A clinical report. *The Journal of Prosthetic Dentistry* 93:6 525-529
- Meskin LH and Gorlin RJ (1963), Agenesia and peg-shaped permanent maxillary lateral incisors, *J Dent Res* 42 (1963), pp. 1476–1479
- Peck L, Peck S and Attia Y (1993) Maxillary canine-first premolar transposition, associated dental anomalies and genetic basis, *Angle Orthod* 63 (1993), pp. 99–109.
- Walls AW, Murray Jfn and McCabe JF (1988) Composite laminate veneers: a clinical study, *J Oral Rehabil* 15 (1988), pp. 439–454
- Witkop Jr CJ and Reynolds JF (1987)

## Case 3

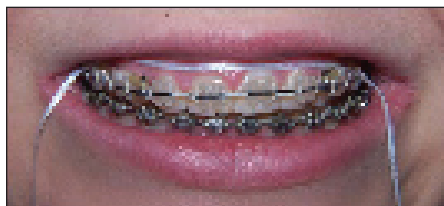


Figure 14: A simple way to assess the discrepancy in gingival heights is to use a piece of floss over the gingivae to assess the differences in the heights of the teeth. In this figure it is evident that the right central is shorter than the left central incisor. It is also evident that the right lateral incisor is shorter in crown length to height of gingiva than the left lateral incisor. In these orthodontic cases, crown lengthening treatment may need to be carried out once teeth are stable in the retention phase

## Case 4

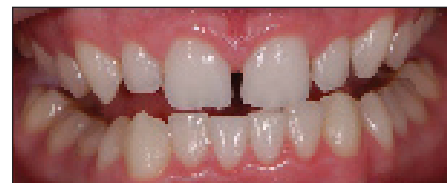


Figure 15: Discrepancy in the size and shape of the centrals and laterals which is discussed with this new patient at the treatment planning appointment once the patients hopes and aspirations for their smile are fully assessed

## Case 5

Patient with upper right peg shaped lateral with gingival discrepancies of right and left sides. Patient had experienced trauma to the upper left central incisor. This tooth developed Calcific Metamorphosis and the tooth shade changed to orange as a result of the trauma. All the teeth were bleached first using 10% carbamide peroxide on home trays. After gingival surgery a period of healing should take place for 6-12 weeks

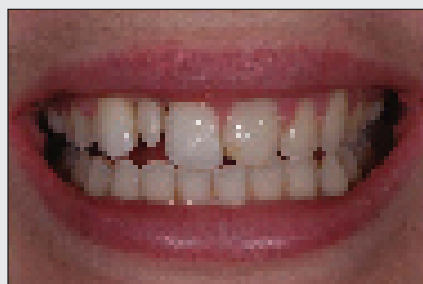


Figure 16: After gingival surgery. Gingival Surgery undertaken by periodontist, Dr Constantine Ong. The importance of continued immaculate oral hygiene is stressed at the post operative appointment. Sutures although dissolving are removed at two weeks post surgery



Figure 17: It is important to use good isolation technique. This procedure was undertaken two weeks after surgery as the patient was travelling abroad for six months. It is best to wait 6-12 weeks after gingival surgery to provide further restorative treatment. That way the gingival contours are fully healed. However as the patient was travelling she needed immediate improvement of the peg shaped lateral prior to travelling. This was undertaken using a direct composite bonding layering technique. Dentine and enamel shades were built into the restoration to give natural translucency and opalescence.

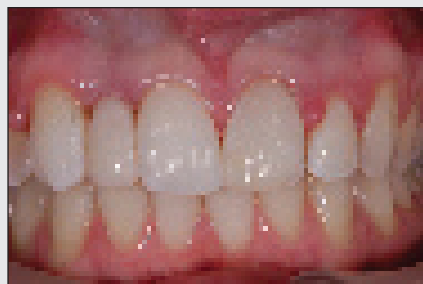


Figure 18: Results after immediate temporary composite bonding. As the patient was travelling abroad for six months, composite bonding was undertaken as an interim measure. This would give immediate improvement of the peg-shaped lateral while further healing of the gingiva could be undertaken. When the patient returns in six months further modifications can be undertaken to tooth contour using further composite bonding where necessary. The development of the gingival papillae around peg lateral will continue as healing progresses

Agnesia of succedaneous teeth: An expression of the homozygous state of the gene for the pegged or missing maxillary lateral incisor trait *American Journal of Medical Genetics* Volume 26, Issue 2, February, Pages: 431-436

Linda Greenwall will be discussing the latest techniques in bleaching and bonding on 23rd April 2010 Royal College of Physicians, London.  
See [www.independentseminars.com](http://www.independentseminars.com) for more information or call 0800 371652